

New Advances in the Management of Lid Margin Disease

Paul M. Karpecki, OD, FAAO
Lexington KY

Lid Disease Fundamentals

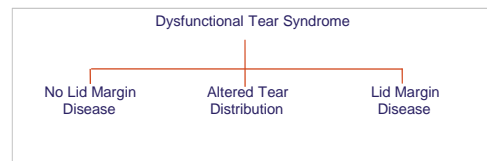
- Association or synonymous with Dry Eye
- Differentiating the various types of blepharitis
- Terminology: MGD, meibomitis etc.
- New understandings of lid margin disease and the components of MGD
- Treatment options
- Communicating that information

Lacrimal Functional Unit (LFU)

- Tear film
- Lacrimal glands
- Corneal and conjunctival epithelia
- Meibomian glands
- Homeostasis controlled by nerve connections and systemic hormones

Barabino S et al. Prog Retin Eye Res. May 2012

DTS: Clinical Categories

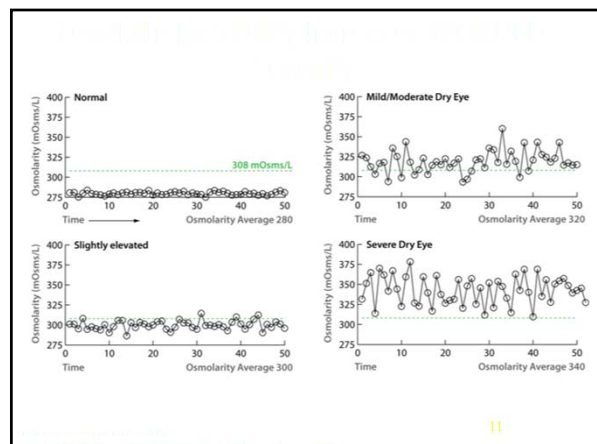


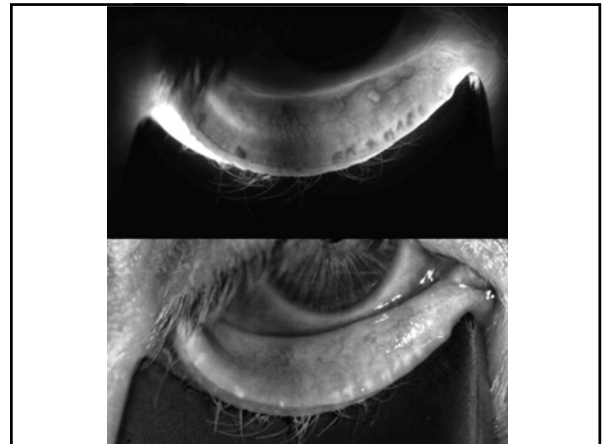
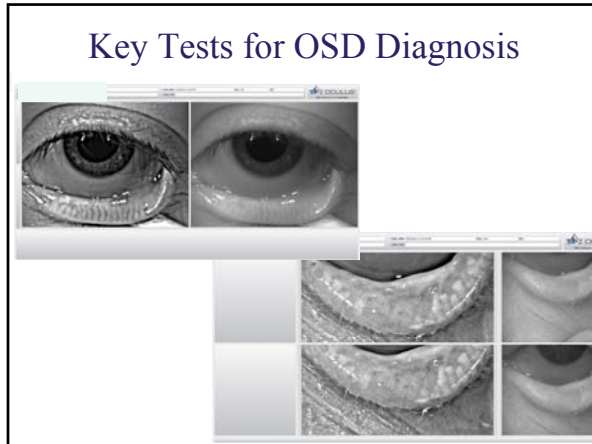- Most common presentation: "No lid margin disease"
- Treatment decision based on severity level

Behrens et al. Cornea 2006

Key Tests for OSD Diagnosis

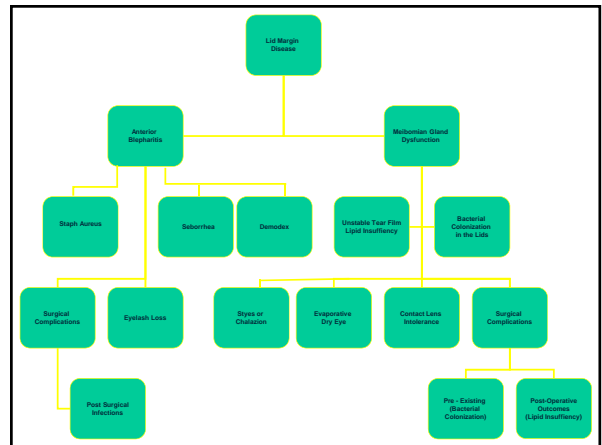
- Questionnaire e.g. SPEED, OSDI etc.
- POC: Osmolarity
- MG Expression
- Ocular surface staining
- Blink analysis
- Meibography may replace previous testing and enhance meibomian gland evaluation





UPPER EYELID:
POSTERIOR ANATOMY

1. Folliculitis - scurf, lash misdirection
2. MGD - evaporative dry eye, early TBUT
3. Lacrimal - Aqueous deficiency
4. Lid laxity - entropion, ectropion, Floppy







Anterior Blepharitis

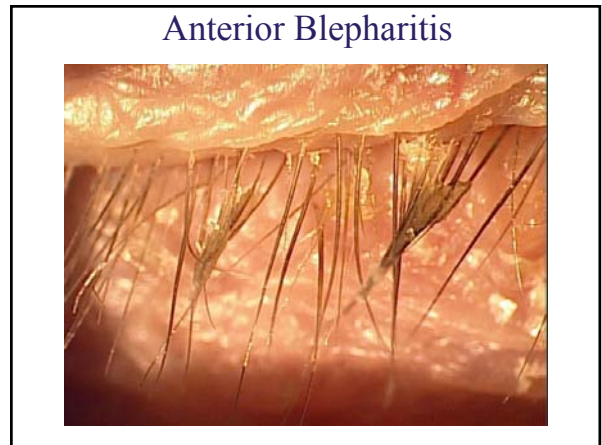
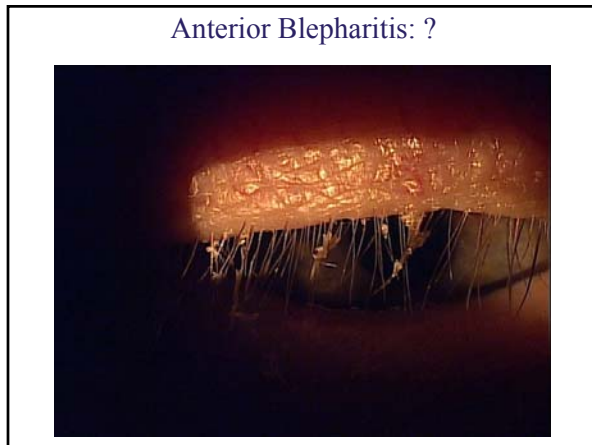
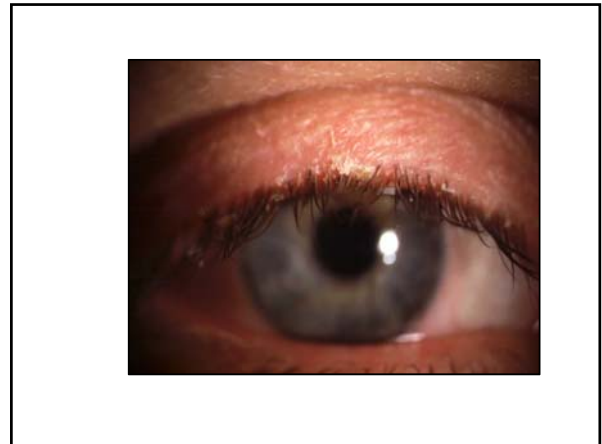
14

Anterior Blepharitis

- Inflammation of the eyelids usually caused by bacterial infection (staphylococcal) of the eyelid margin
- Infection normally occurs at the origins of the eyelashes and involves the lash follicles and the meibomian glands
- Signs and symptoms include:
 - Morning crusting of lids
 - Loss of lashes
 - Collarettes - scales that encircle lash
 - Lid margin redness
 - Conjunctival hyperemia

PROGRESSIVE STAGES OF BLEPHARITIS

<p>Stage 1 Lid margin with minimal scuff, irritation and foreign body (FB) sensation.</p> 	<p>Stage 2 Lid margin with mild scuff, lash matting and follicle swelling, mild inflammation, FB sensation, watery eyes due to over-stimulated tear glands.</p> 
<p>Stage 3 Lid margin with moderate scuff, lash clumping and follicle swelling, more lash matting, moderate inflammation, FB sensation, moderate and early to moderate dry eye. Possible Demodex infestation.</p> 	<p>Stage 4 Lid margin with heavy scuff and crusting, lash follicle swelling, lash matting, severe lashes, severe inflammation with tear gland swelling, impaired meibomian glands and severe dry eye. Possible Demodex infestation.</p> 




Target Profile For Optimal Treatment of Lid Margin Disease

Anterior Blepharitis: Staphylococcal

- *Broad spectrum antimicrobial activity* → eliminate the bacteria in acute cases
- *Anti-inflammatory effect* → reduce the inflammation
- *Good penetration* → high levels at site of disease
- *Long contact time*
- *Convenient dosing* → promote good compliance

Anterior Blepharitis Treatment

- Current treatment options
 - Lid hygiene with hot compresses
 - Commercial lid scrubs
 - Antibiotic ointment to lid margin
 - Corticosteroids for persistent inflammation (Lotemax ung)



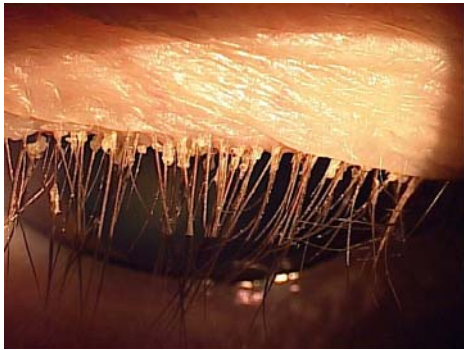
Typical Antibacterial Choices

- Macrolide: erythromycin ung
- Bacitracin ung
- Polysporin ung
- AzaSite

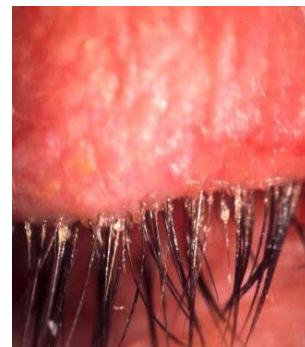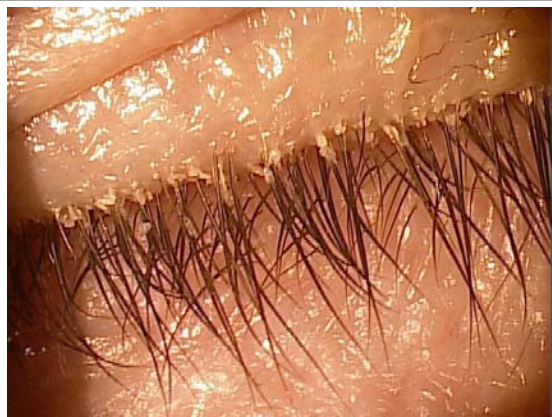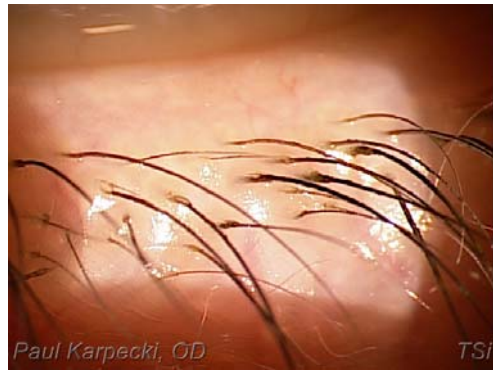Typical Anti-inflammatory Choices

- Combination drops and ointments
- Steroid drops and ointments
- Tobradex, maxitrol, zylet etc.

Anterior Blepharitis: ?



Anterior Blepharitis: ?

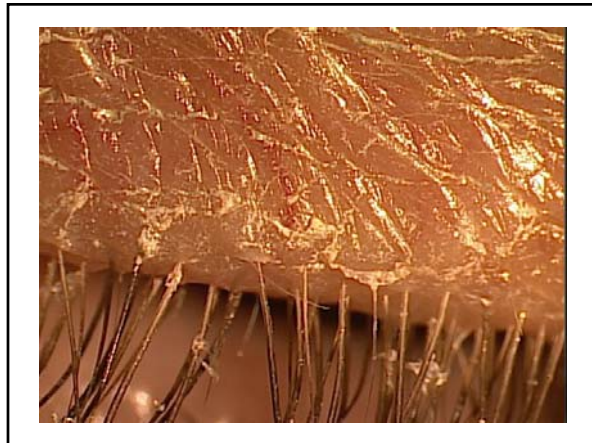
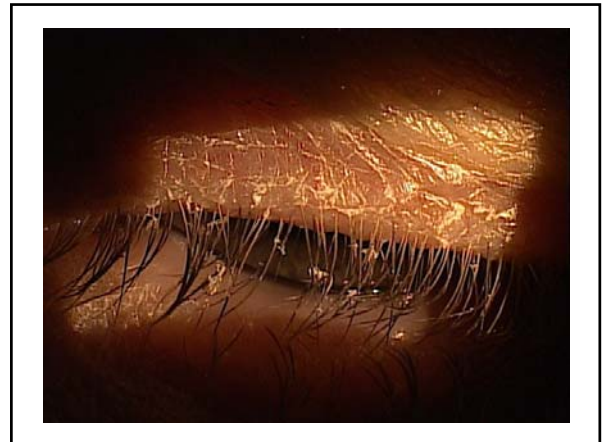


Target Profile For Optimal Treatment of Lid Margin Disease

Anterior Blepharitis: Demodex

- Tea-Tree oil ~ 50%
- Cliradex and Cliradex Complete (4-Terpeniol)
- OcuSoft Demodex Swabstix (contains buckthorn seed oil)
- Make in office?

- Cliradex Lite, SteriLid or Oust for maintenance

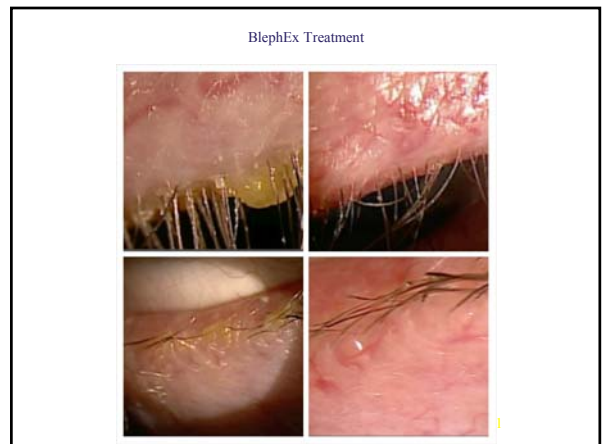


Target Profile For Optimal Treatment of Lid Margin Disease

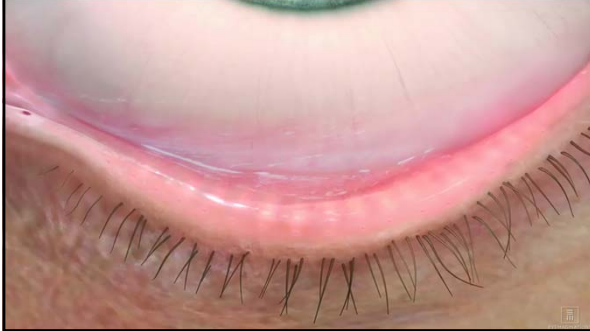Anterior Blepharitis: Seborrhea

- Dermatological prep such as triamcinolone 0.1% cream BID or QD
- No more than 2-3 weeks duration
- Lotemax ointment if fear patient may get in eyes

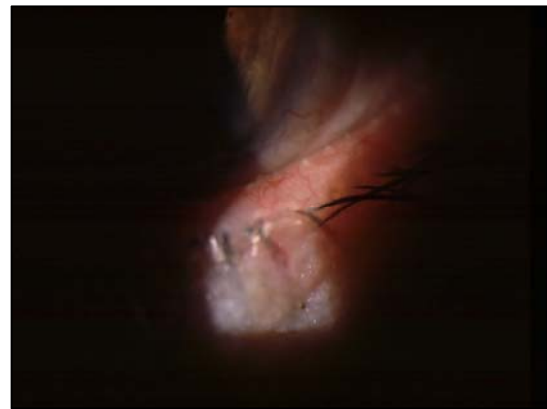
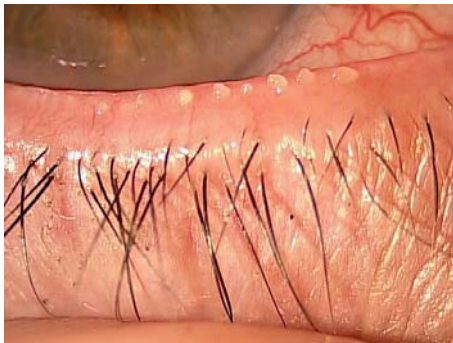
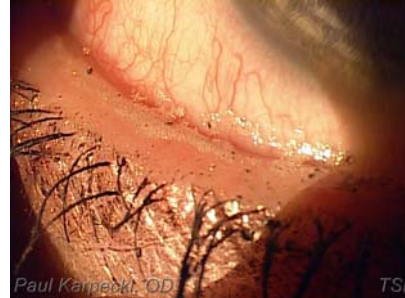- OcuSoft Lid Scrub Plus or iLast Care for maintenance



MGD

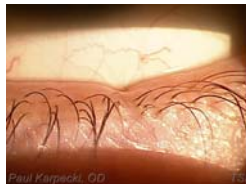
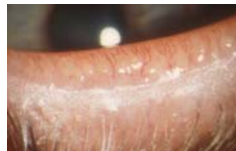
Frothy / Foamy Tears = MGD



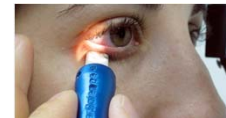Chronic changes

- Telangiectasia
- Scarring



Indications for Use

- Intended for use by a clinician to evaluate Meibomian gland secretions. Used to apply consistent light pressure to the outer eyelid skin of a patient while visualizing secretions from Meibomian gland orifices through a slit lamp biomicroscope.
- NO KNOWN CONTRAINDICATIONS



Four Components to MGD

- Obstruction
- Bacterial biofilm
- Inflammation
- Tear film instability

Matsumoto et al, Graefes Arch Clin Ophthalmol Jan 2009

Mild MGD

- Hot/warm compresses
- Lid hygiene scrubs
- Lipid based tears for mild to moderate
- Omega fatty acid supplements or cyclosporine gtts or lifitigrastr 5%

Moderate/Severe MGD

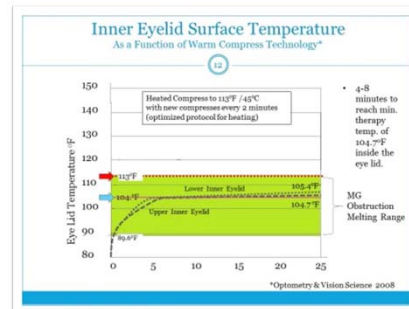
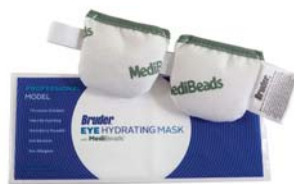- Hot/warm compresses vs. Thermal pulsation
- Blephex biofilm treatment in office
- Retain MGD or osmolarity lowering tears such as TheraTears or Blink
- Steroid combination agents, topical steroids or even oral doxycycline/azithromycin

Obstruction

- Lid margin debridement/scaling
- Commercial WC (e.g. Bruder, TranquilEyes etc.)
- Cold or manual expression
- Mechanical thermal pulsation

Bruder Eye Hydrating Compress

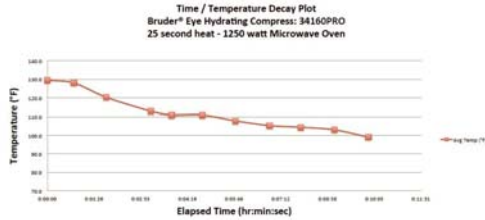
- Moist heat compress
30 angstrom opening pulls in ambient hydration and then release
- 20-25 seconds in microwave
- Brings MG temperature over 104 degrees for ~10 min
- Antibacterial via silver ionization
- Washable, durable



- Heat transfer through lid, tarsal plates to MGs a key challenge
- Heating target should be 45 degrees C (113 degrees F)
- Up to 8 minutes to reach 40 degrees C at inner lid
- Secretions melt at 32-45 degrees C (several factors impact range)

Patented MediBeads Technology

Br
pe
as
(f)



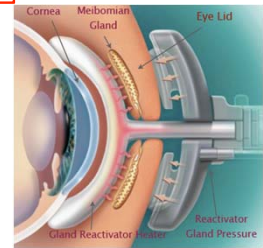
43

A new thermodynamic treatment to express & evacuate the MGs

Heat applied to both **inner lid** surfaces
Pulsatile pressure applied to **outer lids**



The device applies controlled heat to the **inner** upper and lower palpebral conjunctival surfaces and lid margins, while simultaneously applying pulsating pressure over the upper and lower (outer) eyelids.

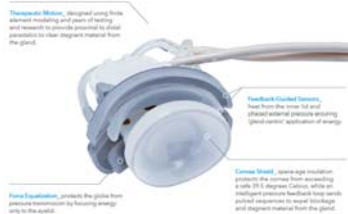

FDA approved LipiFlow July 2011

Core Therapy: Treat obstruction

Novel Approach:
Heat the inner lid surface with simultaneous gland evacuation

- Safe, effective, precise, proven:
- Restores Meibomian Gland function
 - Applies a combination of heat and pressure directly to the inner eyelid
 - FDA-cleared and clinically approved
 - Independent proven results in peer-reviewed studies



1. Finis, D, et al. Ocular Surface 2014 Apr; 12(2): 146-54
2. Greiner, JV. Clin Experiment Ophthalmol. 2013 Aug;41(6):524-30
3. Blackie CA, et al. Treatment for meibomian gland dysfunction and dry eye symptoms with a single-dose vectored thermal pulsation: a review. Current Opinion in Ophthalmology 2015, 26:306-313.

LipiFlow® Thermal Pulsation

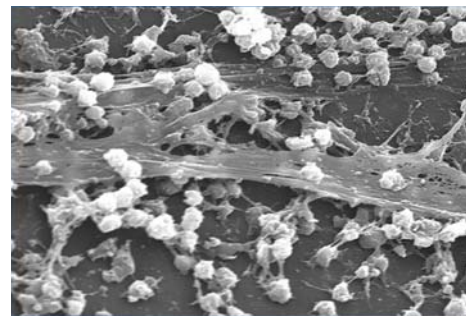
LipiFlow® is the only FDA-cleared device for Meibomian Gland Dysfunction (MGD), shown to restore gland function.

LipiFlow® is an in-office procedure, taking only 12 minutes per eye.

Does LipiFlow® Work?

- A recent review of 31 peer reviewed articles/abstracts (including five registered randomized controlled clinical trials):
A single dose, 12-minute therapy results in:
 - Mean gland function improvement is ~ 3x baseline
 - Mean symptom improvement is ~ 2x (symptoms are halved)
 - Sustained effect:
 - Nine center randomized controlled study: mean improved gland function and symptom relief was 12 months and longer.
 - Uncontrolled studies: significantly longer (these include combination therapy, lid margin health)

1. Blackie CA, et al. Treatment for meibomian gland dysfunction and dry eye symptoms with a single-dose vectored thermal pulsation: a review. Current Opinion in Ophthalmology 2015, 26:306-313.




44


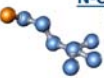
Treating the BioFilm

- BlephEx
- Avenova Cleanser from NovaBay or HypoChlor from OcuSoft
- Surfactant Based Lid Hygiene products e.g. Lid Scrub Plus, SteriLid etc.
- Surfactant + anti-inflammatory agents (phytosphyngisine): OcuSoft Platinum
- Antibiotics etc.

White Blood Cell in Action



Invading Microbe
White Blood Cell
Red Blood Cells

 <p>Hypochlorous Acid (HOCl) Natural Compound NVC-101 – Stable Formulation Rapid Acting</p>	 <p>N-Chlorotaurine (NCT) Natural Compound Rapid Acting Effective BUT Unstable</p>
---	---

OCuSOFT® Lid Scrub® PLUS PLATINUM

- Mild surfactants in OCuSOFT® Lid Scrub® eyelid cleansers act to dissolve and remove oil, debris and dead skin from the eyelids. OCuSOFT® Lid Scrub® PLUS PLATINUM is an extra strength eyelid cleanser containing PSG-2™
- PSG-2 is a water-binding agent that mimics the natural lipid layer of the skin for increased moisturizing throughout the day.
- Has also been reported to have both antibacterial and anti-inflammatory properties.

Treating Inflammation

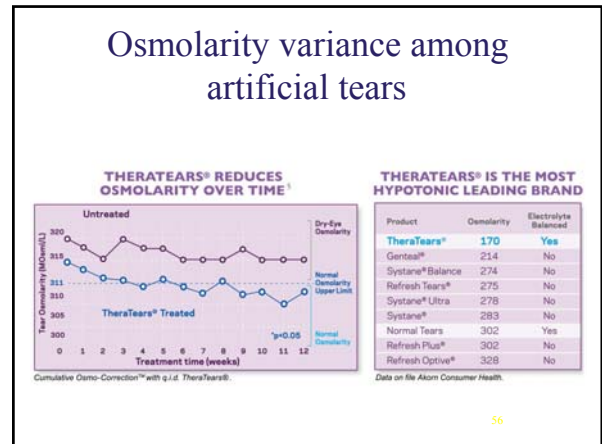
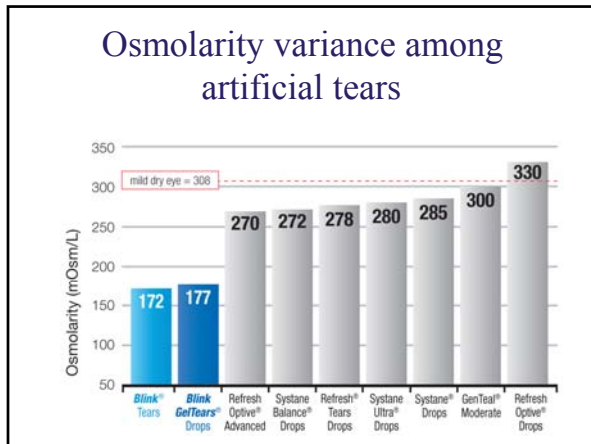
- Combination agents bid
 - Zylet, Tobradex, Tobradex ST, Maxitrol etc.
- AzaSite QHS
- Steroid ointments (Lotemax, FML, Maxitrol etc)
- Oral Doxycycline (50mg or 20mg)
- Nutritional supplements (EPA/DHA/GLA)

Tear Film Alterations

- Choice of artificial tears depends on two things:
 - MG expression
 - Osmolarity

Tear Film Alterations

- Choice of artificial tears:
 - High osmolarity/advanced MGD:
 - Blink or TheraTears or RetainMGD
 - Low osmolarity/moderate MGD:
 - Systane Balance, Refresh Optive Advanced, RetainMGD, SootheXP



MGYLS

- Symptomatic CL wearer: 4.8
- Asymptomatic non-CL: 5.5
- Asymptomatic RGP wearer: 9.0
- Asymptomatic SCL wearer: 10.7

Potential Theories on major causes of the high incidence of MGD in North America

- Diet
- Hormonal
- Contact lens wear (Villani E et al)
- Digital device use
- Systemic disease
- Heredity

One Potential Theory on a major cause of the high incidence of MGD in North America

TREATMENT

Mild MGD

- Hot/warm compresses
- Lid hygiene scrubs
- Lipid based tears for mild to moderate
- Omega fatty acid supplements or cyclosporine gtts

Liposome Spray

- Self-closed colloidal particles
- Membranes composed of one or more lipid bilayer(s)
- The surfaces of bilayers are hydrophilic while the interior, which contain hydrocarbon chains, are hydrophobic
- Because of the different microenvironments in their structure, liposomes can encapsulate hydrophilic molecules
- Applications for lid disease but also drug delivery, diagnostics, computer vision syndrome and nutraceuticals

53

Moderate/Severe MGD

- Hot/warm compresses vs. Thermal pulsation
- Blephex biofilm treatment in office
- Retain MGD or osmolarity lowering tears such as TheraTears or Blink
- Steroid combination agents, topical steroids or even oral doxycycline/azithromycin

Moderate anti-inflammatory

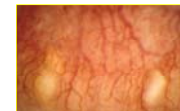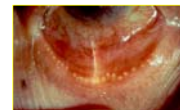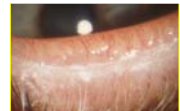- Zylet
- Tobradex ST
- Tobradex
- Maxitrol
- AzaSite
- Lotemax ung or FML ung QHS

Long Term

- Eye Hydrating compress daily
- Lid hygiene daily- foam canisters
- Pulse dose medications periodically
- Cyclosporine BID
- Steroids when symptoms are worse
- Essential fatty acid supplements

Potential Chronic Changes

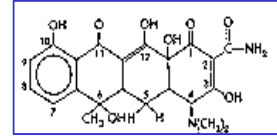
- Telangiectasia
- Dislocation of meibomian glands/ gland atrophy
- Scarring/atrophy



Moderate/severe or not improving

- Add PO tetracycline
- Recommendation:
- Doxycycline 50mg bid x 4-8 weeks then taper to qd
- Doxycycline 20 mg bid (periostat can be expensive)
- Time Release 40mg (can be expensive as well)

Tetracyclines



- Antibiotics inhibit bacterial protein synthesis by binding 30S ribosome
- Anti-inflammatory properties
 - decreases IL-1, TNF- α
 - decreases NO production
 - decreases HLA Class II antigen expression
 - decreases metalloproteinase production and activation
- Decrease symptoms and joint destruction in RA

Contraindications

- Pregnant, nursing or female of child bearing age
- Children

Tetracycline

- Pregnancy ratings:
 - A, B, C, D, X
- Rating on tetracycline: D

Cautions

- Photosensitivity
- Chelates with dairy products, antacids etc.
- Minocycline may cause vestibular toxicity
- Risk of IIIH
- Number one drop-out reason?
- GI problems

How to Minimize Stomach Problems with Tetracycline

1. Do not take the second pill (bid) before going to bed
2. Do not take pills with acidic beverages
3. Take pills with food (except a high dairy meal)
4. Prescribe the lowest dose available
5. Prescribe the hyclate form

Nutritional Supplements: Essential Fatty Acids

- Omega fatty acids shown to help with dry eye disease:
 - ALA: e.g., flaxseed oil
 - EPA/DHA: e.g., fish oils
 - GLA: e.g., black currant seed or evening primrose oil



Effect of Essential fatty acids on MGD inflammation

- Role of good Omega-6 (GLA) vs. Omega-6 LA vs. lid hygiene (control)
- 57 patients randomized and analyzed MG secretions, obstruction, hyperemia and staining
- Statistically significant improvement in ALL groups on GLA compared to LA or lid hygiene

Pinna A et al. Cornea Apr. 2007


Omega fatty acids and Dry Eye

- LA / GLA (ω -6)
 - Increase "good" PG (PGE-1)
 - Against ocular surface inflammation
 - Increase tear production
- Positive action on lipid layer (Graham RH. There's nothing fishy about omega-3 fatty acids for Dry Eye Syndrome. www.medscape.com/viewarticle/707984. Sep 3, 2010.)
 - Positive action on tear volume (Roncone M, Bartlett H, Eperjesi F. Essential fatty acids for dry eye: A review. *Cont Lens Anterior Eye* 2010; 33(2):49-54.)
- Help to maintain MG function (Macasai, 2008)


Omega and Dry Eye

- ALA (ω -3; flaxseed oil)
 - Helps to restore ocular health
 - Blocks cytokine release (IL-1) and release of necrosis factors (TNF- α)
 - Reduce local leukocytes action
 - Contra-indicated if GI problems or history of prostate disease
 - Conversion rates in men











Omega and Dry Eye

- EPA/DHA
 - Cold water fish
 - More absorption
 - Triglyceride vs. Ethyl Ester
 - USP Certified
 - Dosing?
 - Depends on 2 key things
 - Current level of nutrition
 - Current disease state
 - Contraindications
 - Blood thinners?



MGD is Progressive

	Normal Function	Nonobvious MGD	Obvious MGD	Obvious MGD
Function				
Structure				

Notes: Siak JJ, et al. Prevalence and risk factors of meibomian gland dysfunction: the Singapore Malay Eye Study. *Cornea*. 2012;31(11):1223-1228.
 Viso E, et al. Prevalence of asymptomatic and symptomatic meibomian gland dysfunction in the general population of Spain. *Invest Ophthalmol Vis Sci*. 2012;53(6):2601-2606.
 Horn MM, et al. Prevalence of meibomian gland dysfunction. *Optom Vis Sci*. 1990;67(9):710-712.

GLAUCOMA SIMILARITY

- Look at the structure and functioning of the MGs and ocular surface
- Multiple testing:
- IOP = osmolarity
- VF testing = corneal staining
- OCT = meibomography
- MG expression = ONH examination

82

FUTURE: DENTAL MODEL

- Tooth brush & floss = Hydrating compress and lid hygiene and ATs
- Dental cleaning = mechanical cleaning and MG expression (mechanical or otherwise)
- Dental x-rays = meibomography

83

paul@karpecki.com

www.opthalmicresources.com